



CASE- REPORT

Sarcoidal Granuloma in Cervical Lymph Node: case report

ENT Department, Rabat Specialty Hospital, Ibn Sina University Hospital, Hafiane-Cherkaoui Avenue, 10100 Rabat, Morocco

El Messaoudi Lina^{1,3*} | Bencheikh Razika^{2, 3} | Benkhraba Neima^{1,3} | Benbouzid Mohamed Anas^{2,3} | Leila Essakalli Houssyni^{2,3}

¹ Consultant otolaryngology surgeon, AlResident physician in otorhinolaryngology, Department of Otorhinolaryngology, Head and Neck Surgery, Ibn Sina University Hospital, Rabat, Morocco.

² Professor of otorhinolaryngology, Department of Otorhinolaryngology, Head and Neck Surgery, Ibn Sina University Hospital, Rabat, Morocco.

³ Faculty of Medicine and Pharmacy of Rabat, Mohammed V University, Rabat, Morocco.

Abstract

Sarcoidosis is a multi-system granulomatous disease of unknown etiology. The presentation of sarcoidal granuloma in neck nodes without typical manifestations of sarcoidosis is difficult to diagnose. We describe the case of a 60-year-old woman with a left latero cervical lymphadenopathy, The excisional biopsy from the neck mass showed noncaseating epithelioid cell granuloma and th immunohistochemistry confirmed the diagnosis of gonglion sarcoidosis. Keywords: sarcoidosis ,granuloma, lymph node.

Copyright : © 2022 Medical Editor and Educational Research Publishers

1 | INTRODUCTION

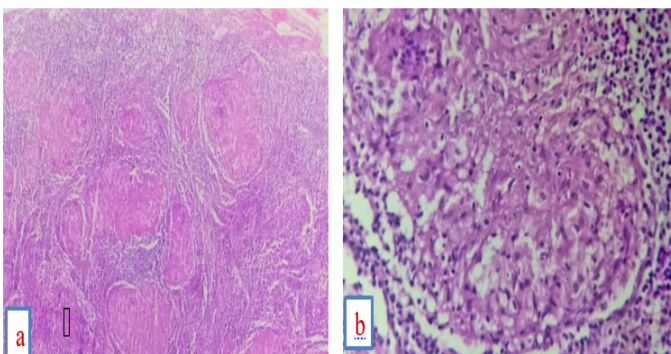
Sarcoidosis is a systemic granulomatous disease of unknown cause ; Characterized by the infiltration of organs affected by epithelioid immune granulomas and gigantocellular cells (also called tuberculoid granulomas) without caseous necrosis; diagnosis requires ruling out the known causes of granulomas. It commonly affects young

to middle-aged adults with pulmonary involvement seen in majority of cases. Thoracic involvement with sarcoidosis is characterized by bilateral hilar lymphadenopathy with or without pulmonary parenchymal abnormality. The presentation of sarcoidal granuloma in peripheral lymph nodes, without clinical findings suggestive of sarcoidosis elsewhere, poses a diagnostic problem. Our patient had a sarcoidal granuloma restricted to cervical lymph nodes and a suspected diagnosis of sarcoidosis. It should be emphasized that in patients

who present with sarcoidal granuloma in peripheral lymph nodes, a diagnosis of sarcoidosis may only be made months or years later.

2 | CASE REPORT

A 60-year-old female patient presented with a left latero cervical mass for 2 years. She had no associated symptoms (no dyspnea or, chest pain, fatigue, fever or weight loss) and the physical examination revealed multiple palpable, nontender, firm and mobile lymph nodes in both sides of the neck. The largest node was about 2 cm on the left side of her neck but no splenomegaly or hepatomegaly. the patient underwent a cervical ultrasound and a cervico-thoracic TDM; revealing a magma of cervical lymphadenopathy, the largest of which is on the left . the patient was operated under general anesthesia: left cervicotomy;the definitive anathomopathologic result was in favor of a gonglionic sarcoidosis. the postoperative consequences were simple and the patient was put on corticosteroid therapy. No recurrence of the neck mass, or signs of other systemic sarcoidosis, were found in the followup period of 3 years.



Histologic appearance of our patient showing a lymph-node with typical sarcoid:

- (a) Epithelioid granulomatous lesion with central necrosis and multinucleated giant cells
- (b) High magnification of (a) shows hyalinized necrosis and surrounding epithelioid

3 | DISCUSSION

Sarcoidosis is an inflammatory systemic disease characterized by noncaseating granulomas composed of epithelioid giant cells, macrophages, and lymphocytes. Cervical lymphadenopathy is the most common head and neck manifestation of sarcoidosis, but sarcoidosis only accounts for 1.7% of all head and neck lymphadenopathy the diagnosis of sarcoidosis is based on physical examination, radiologic and laboratory findings, and is supported by histologic evidence of noncaseating epithelioid-cell granulomas in one or more organs in the absence of organisms or particles.

Sarcoidal granulomas have no unique histologic features to differentiate them from other granulomas, Although the cause of sarcoidosis remains unknown, immunologic mechanisms, genetic susceptibility, and infectious and environmental agents have all been implicated as possible factors. An antigen-driven, cellmediated immune response in tissues affected by sarcoidosis leads to a cytokine cascade and to granuloma formation that is thought to be mediated by stimulation of CD4 T lymphocytes/T helper cells through macrophage-presented antigen.^{1,3,7} Sarcoidosis is genetically a complex disease, the most prominent finding of which is a link to a region containing the major histocompatibility complex on the short arm of chromosome 6. A positive association with human leukocyte antigen-B8 and -DR3 has also been reported. Various infectious and environmental agents may be causative factors of sarcoidosis, but such agents have not yet been definitively identified or proven. Cervical lymphadenopathy is difficult to distinguish from other granulomatous diseases and malignancy.

Supplementary information The online version of this article (<https://doi.org/10.52845/JORR/2022/3.2.3>) contains supplementary material, which is available to autho-rized users.

Corresponding Author: *El Messaoudi Lina Consultant otolaryngology surgeon, Alhabbobi teaching hospital, otolaryngology department, F.I.C.M.S., C.A.B.S, college of medicine, university of Thi-Qar*

TNF- α can be an adjuvant indicator of sarcoidosis. In the present case, abundant expression of TNF- α was noted in the granuloma, supporting the diagnosis of sarcoidosis. TNF- α is also thought to play a major role in the proliferation and spontaneous activity of macrophages and Tlymphocytes at the sites of inflammation and in the formation of noncaseating granuloma⁹. Therefore, TNF- α inhibitors may have a therapeutic effect on granulomatosis, such as that in the present case.

Since many clinical conditions can result in sarcoid like granuloma, the diagnosis of sarcoidosis is also established by exclusion of other granulomatous diseases such as Wegener's granulomatosis, lymphoma, carcinoma, fungal disease, foreign-body reaction, berylliosis, syphilis, and infection with *Mycobacterium tuberculosis*. The latter infection is the most likely differential diagnosis, and some authors think that *M. tuberculosis* may play a role in the pathogenesis of sarcoidosis. The detection of DNA from *M. tuberculosis* by PCR has been described as a highly specific and sensitive method for diagnosing tuberculosis; this method can also be used to exclude *M. tuberculosis* as the cause of sarcoidosis. When there is no clinical picture suggestive of the diagnosis, the presence of giant cell granuloma is of low value because it is not specific for sarcoidosis.

Many agents can cause a granulomatous reaction including inert particles from the environment: beryllium, zirconium salts, titanium, aluminum, talc; infectious agents: bacteria (*mycobacterium tuberculosis*, *m. leprae*, atypical *m.*, *brucella*, *chlamydia*, *tularemia*, *treponema*, *barthionella*, *p. pseudomallei*), fungi (*histoplasma*, *coccidioidomyce*), parasites (*leishmania*, *toxoplasma*); drug antigens or environmental antigens inducing hypersensitivity. Granulomatous reactions may be observed in dysimmune pathologies (*Wegener's granulomatosis*, *primary biliary cirrhosis*, *Churg and Strauss syndrome*, *Crohn's disease*, *Gougerot Sjögren syndrome*, *immunoglobulin deficiency*). Localized sarcoid-like granulomatous reactions can accompany a tumor, whether it is lymphoma or epithelial malignancies.

Treatment is recommended to preserve organ function, relieve symptoms, or both, and

corticosteroids are currently the treatment of choice. Antimalarial drugs, immunosuppressant drugs, immunophilins, and anti-tumor necrosis factor drugs have recently shown some success in the treatment of sarcoidosis.⁸ During follow-up, clinicians should assess the involvement of critical organs, such as the lungs, heart, brain, liver and kidneys, and should provide routine evaluations every 2–4 months according to clinical need.

4 | CONCLUSION

In summary, sarcoidosis should be included in the differential diagnosis of cervical lymphadenopathy. Sarcoidal granuloma in peripheral lymph nodes may precede a diagnosis of systemic sarcoidosis, and regular follow-up of patients with such granuloma is highly recommended.

REFERENCES

1. Sarcoidal Granuloma in Cervical Lymph Nodes Hsin-Chien Chen, Bor-Hwang Kang, Chuan-Tsai Lai1, Yaoh-Shiang Li
2. Sarcoidosis in the Head and Neck: An Illustrative Review of Clinical Presentations and Imaging Findings Margaret N. Chapman^{1,2} Akifumi Fujita^{1,3} Edward K. Sung^{1,4} Cory Siegel^{1,2,4} Rohini N. Nadgir^{1,5} Naoko Saito⁶ Osamu Sakai¹.
3. Cervical Lymph node sarcoidosis Mimicking a parathyroid Adenoma: A clinical case pietro Giorgio Calò, Giuseppe pisano, Alberto Tatti
4. Neck as mediastinal extension: Diagnosis of sarcoidosis by core biopsy of cervical lymph nodes Ahmed Fahim¹ | Muhammad Mahzooz Qasim¹ | David Rosewarne
5. Isolated Cervical Lymph Node Sarcoidosis Presenting in an Asymptomatic Neck Mass: A Case Report Yong Shik Kwon, M.D.¹, Hye In Jung, M.D.¹, Hyun Jung Kim, M.D

6. Localisations ORL au cours de la sarcoïdose : à propos de 2 observations I. Kechaou, M. Tougorti , E. Cherif, W. Ban
7. Panuvéite bilatérale granulomatose : pensez à la toxocarose ! Y. Fekih1, , F. Daoud2, A. Kefi3, L. Baili2, A. Chebb
8. Les manifestations extrathoraciques au cours de la sarcoïdose M. Jebri1, , I. Kechaou2, I. Boukhris3, A. Hari

How to cite this article: El Messaoudi Lina ET AL. Sarcoidal Granuloma in Cervical Lymph Node: case report Journal of Otolaryngology and Rhinology Research. 2022;86–89 . <https://doi.org/10.52845/JORR/2022/3.2.3>
