



ORIGINAL-RESEARCH ARTICLE



Surgical Drain Placement Technique and Its Effects Following Total Laryngectomy

Traeden Wilson, BS ¹ | Donald Solomon, MD ^{1,2} | Nadir Ahmad, MD ^{1,2} | Luke Stanisce, MD ² | Justin Ungerleider, BS ¹ | Krystal Hunter, PhD ³ | Yekaterina Koshkareva, MD ^{1,2*}

1. Cooper Medical School of Rowan University, Camden, NJ
2. Division of Otolaryngology – Head & Neck Surgery, Cooper University Health Care, Camden, NJ
3. Cooper Research Institute, Cooper University Health Care, Camden, NJ

Abstract

Objective: We aimed to determine whether securing Jackson-Pratt (JP) drains with suture both internally and externally (IE) vs. externally only (EO) after total laryngectomy affects drain migration and incidence or rate of postoperative complications.

Study Design: Retrospective chart review.

Setting: Single institution urban tertiary care center.

Methods: Fifty-three patients who underwent total laryngectomy were reviewed retrospectively and categorized as IE or EO. Post-operative esophagograms were reviewed by 12 non-affiliated Otolaryngologists. Drain displacement, post-operative complication rates and time to detection of complication were compared.

Results: Fewer radiographs (20.7%) were designated as "displaced" in the IE group compared to the EO group (30.4%) ($p = 0.05$). There was no difference in complication rates or median time to detect salivary leaks between the two groups.

Conclusion: The utilization of an internal suture technique to secure surgical drains following total laryngectomy was associated with a decreased rate of drain migration. However, drain migration did not appear to affect complication rates or timing of detection of a salivary leak.

Keywords: laryngectomy, surgical drains, wound complications

Copyright: © 2023 Medical Editor and Educational Research Publishers Ltd

1 | INTRODUCTION

Despite contemporary advances in non-surgical treatment modalities of laryngeal cancer, total laryngectomy remains a mainstay option for patients with advanced tumors, persistent or recurrent disease, and non-functional larynges. Of the complications inherent to the procedure, pharyngocutaneous fistula (PCF) and salivary leak carry significant risk

of morbidity and mortality.⁽¹⁾ The placement of closed drainage systems within the operative field aims to promote egress of fluid from the surgical bed.⁽²⁾ Additionally, the monitoring of drain output provides insight to the healing process, as changes in the quality and quantity often herald the development of complications, such as hematoma or chyle or salivary leak.

It is our institutional practice to place closed jackson

Pratt (JP) drain systems in proximity to the pharyngeal closure after a total laryngectomy and maintain its presence until esophagograms are obtained on postoperative day 7. The rationale is to egress fluid to promote healing and provide an internal monitor following the initiation of oral feeding. Further, the retainment of this drain can serve as the initial treatment of any salivary or chylous leak that develops. Traditionally, the drains have been sutured to the skin only, to keep them from getting dislodged. However, a larger operation (such as a total laryngectomy), creates a larger surgical basin, which potentially leaves more room for the drain to move and migrate from the initial placement site. Hence, some of our faculty started securing the post-laryngectomy drains internally to decrease that possibility.

Herein, we aimed to determine whether securing Jackson-Pratt (JP) drains with suture externally only (EO) vs. both internally and externally (IE) after total laryngectomy affects surgical drain migration rates. Secondly, this study analyzed whether internally securing the drains impacts the incidence or detection of postoperative complications including PCF.

2 | METHODS

This study was reviewed and approved by the Cooper University Hospital Institutional Review Board (IRB) and written/verbal consent was obtained for all study subject prior to research activity. The investigators retrospectively reviewed all patients who underwent total laryngectomy at our academic tertiary-care institution from 2014 to 2019. All the surgeries were done by our two fellowship trained Head and Neck Surgeons. The study cohort included all patients who underwent primary neopharyngeal closure, had a postoperative esophagogram study, and were over the age of 18. Subjects who underwent free or pedicled flap reconstruction or had follow-up of less than three months duration were excluded from the study sample. The primary outcome of interest was the difference in the rates of surgical drain displacement from the neopharyngeal bed between the two techniques (EO vs IE). Secondary endpoints of interest were the differences in both the incidence and timing until detection of post-operative compli-

cations. Predictors analyzed included various demographic (age, gender, BMI), treatment (prior radiation, prior chemotherapy, attending surgeon, EO vs IE, complications), and time (duration from surgery to complication, duration to esophagogram, length of postoperative admission) variables. Each subject's electronic medical records were independently reviewed, and data was extracted into a secure study database.

Every patient underwent a T-shaped or linear primary pharyngeal mucosal closure using a running Connell stitch and Lembert sutures followed by select muscular reinforcement sutures and appropriate inferior and lateral myotomies. One to four suction drains were placed: one in each lateral neck gutter and one or two over the midline nasopharyngeal closure. In the IE group, 3-0 vicryl interrupted sutures were used to loosely secure the drain over the pharyngeal closure to the adjacent constrictor muscles (**Figure 1**). All drains were then externally secured using 4-0 nylon or prolene sutures in the standard roman sandal fashion. All incisions were closed in a multi-layer fashion with absorbable stitches and/or skin staples. Scout radiographs from post-operative esophagograms were collected and de-identified for each subject. To determine if drains were displaced, the radiograph images were sent to 12 board-certified otolaryngologists at four, non-affiliated, tertiary care centers in our region as a blinded survey. Each reviewer was asked to score the position of the drain in the image as "non-displaced," "displaced," or "cannot be determined" in relation to the pharyngeal closure site. Example radiographics of subjects receiving scores of "displaced" and "not displaced" are shown in (**Figure 2**). The scores from each reviewer were collected and secondarily compiled as total counts for each subject.

Descriptive statistics were calculated for the cohort. Signed ranks sums testing was used to estimate the difference in rates of displacement between the EO

Supplementary information The online version of this article (<https://doi.org/10.52845/JORR/2023/4.3.1>) contains supplementary material, which is available to authorized users.

Corresponding Author: *Yekaterina Koshkareva, MD*
Division of Otolaryngology–Head and Neck Surgery
Cooper University Health Care, Three Cooper Plaza,
Suite 404 Camden NJ, 08103. E-mail: [koshkareva-](mailto:koshkareva-yekaterina@cooperhealth.edu)
yekaterina@cooperhealth.edu

and IE groups. Chi square, Fishers Exact, and Mann Whitney U testing was performed to analyze differences in postoperative complication incidence and time to detection amongst the two groups. A two-sided critical value of $p < 0.05$ was used to define significance. All statistical analysis was conducted using SPSS (IBM SPSS Statistics Software, Version 27.0. Armonk, NY, USA).

Figure Legend

Figure 1. Scout x-ray captured during barium swallow study demonstrating position of Jackson Pratt (JP) drains. Left image shows JP-drains frequently designated as “not displaced”. Right image shows JP-drains frequently designated as “displaced”.

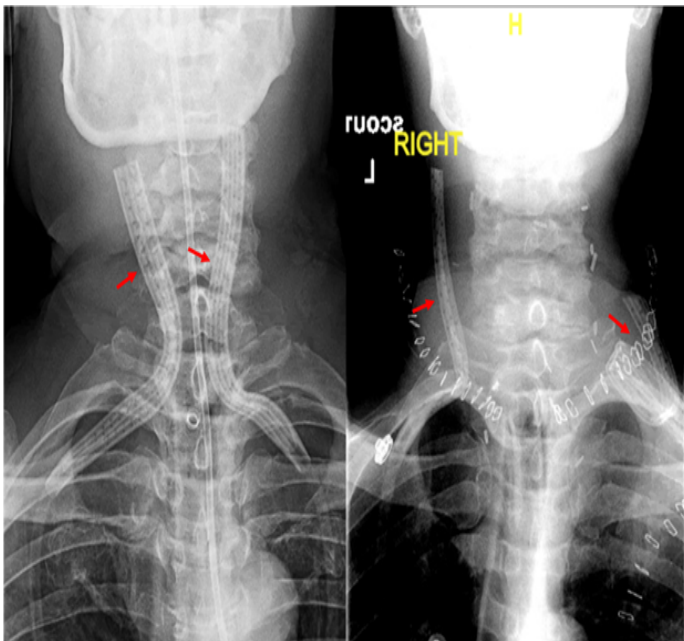


Figure 1: The left image shows a scout radiograph following total laryngectomy with non-displaced JP drains (red arrows). The right image shows a scout radiograph following total laryngectomy with displaced JP drains.

Figure 2. Jackson Pratt (JP) drains with internal suture. 3-0 Vicryl interrupted suture loosely securing the drains to overlying constrictor muscles

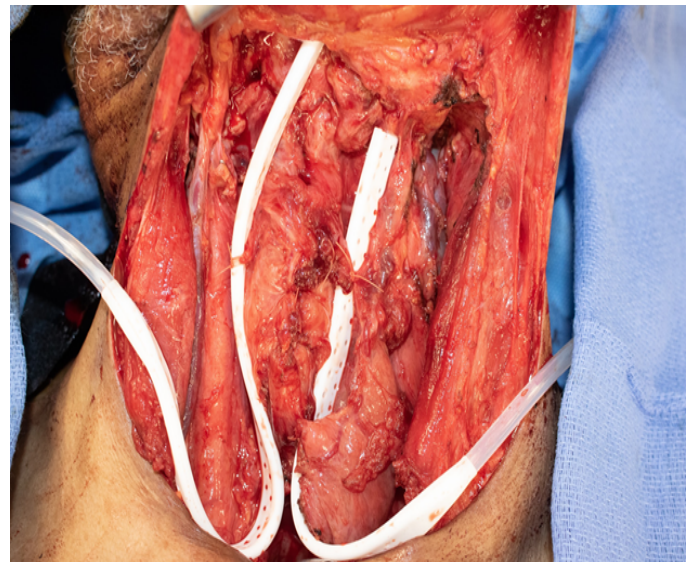


Figure 2: Bilateral JP drains with internal sutures secured to the strap muscles following total laryngectomy.

3 | RESULTS

In total, 53 subjects were included in the study cohort. Twenty-eight (53%) had drains secured EO and 25 (47%) had drains secured IE. There were no differences in patient age, gender, BMI, or prior radiation therapy between the two groups. Cohort characteristics are summarized in **Table 1**.

Table 1. Cohort characteristics demonstrating median age, gender, mean BMI, and history of prior radiation. Cohort characteristics are stratified by use of suture externally only or both internally and externally.

Patient characteristic	External Only (EO) (n = 28)	Internal and External (IE) (n = 25)	P value	Total (n = 53)
Age, median	62.6	65.3	0.32	–
Gender – male	19	17	0.99	37
BMI, mean	23.3	24.5	0.55	–
Prior Radiation (%)	10 (36)	5 (20)	0.24	15 (28)

Twelve board-certified physicians completed the survey. Fewer radiographs (20.7%; [95CI:10.4-30.9]) were designated as “displaced” in the IE group compared to the EO group (30.4%; [95CI:3.4-37.3])

(p = 0.05). Similarly, 61.9% of subjects were designated as “non-displaced” in the IE group compared to 44.9% in the EO group (p = 0.003). The median time from surgery to esophagogram was 7 days for both groups between the two groups (p= 0.52). **Table 2** illustrates the difference in drain displacement between the two groups.

Table 2. Comparison of proportions of radiographs designated as “displaced” or “not displaced” between drains sutured externally only and both internally and externally.

	External Only (95% CI) (n = 28)	Internal and External (95% CI) (n = 25)	P value
Displaced, %	30.36% (23.42-37.30)	20.67% (10.35-30.99)	0.05
Non-displaced, %	44.94% (36.76-53.12)	61.99% (54.07-69.91)	0.003

Seventeen patients experienced postoperative complications: pharyngeal leak (n=14), wound dehiscence (n=2), and wound infection (n=1). There was no significant difference in the rate of complications between the EO (36%) and IE (28%) groups (p = 0.572). Salivary leak developed in nine and five patients in the EO and IE groups, respectively (p = 0.365). There was no difference in the median time to detect salivary leak (7 days) in either group. **Table 3** summarized complications between the two groups.

When comparing subjects with complications to those without, no difference was observed in the distribution of displaced drains (p = 0.583).

Table 3. Comparison of rates of total complications, salivary leak, wound dehiscence, and infection between drains sutured externally only and both internally and externally.

Complication	External Only (EO) (n = 28)	Internal and External (IE) (n = 25)	P value
Total Complications	10	7	0.572
Salivary Leak	9	5	0.365*
Wound Dehiscence	1	0	–
Infection	0	2	0.218*
*Fishers Exact Test			

4 | DISCUSSION

This study aimed to determine the efficacy and utility of internally securing surgical drains with suture following a total laryngectomy. It was hypothesized that suturing drains internally at the neopharyngeal closure site would lead to lower rates of displacement, which would secondarily impact both the timing of detection and incidence of complications including PCF.

The results of our blinded radiographic analysis demonstrate that internally securing surgical drains reduces the rate of displacement from the neopharyngeal closure bed. Nearly 62% of drains were designated “non-displaced” when internally secured, compared to only 45% when only externally secured (p = 0.003). This data shows that the internal suture technique is efficacious in maintaining the drain in its intended position.

Surgical drain placement at the time of surgery is a common practice that promotes wound healing by limiting fluid accumulation and enhancing the local environment.(3) Successful drain function relies on proper positioning and various studies have investigated differences in drain securing techniques. Heskin et al. demonstrated superior drain fixation with the external centurion sandal method compared to the double and multiple loop techniques.(4) Others propose the use of additional external sutures to prevent displacement.(5),(6) To the author’s knowledge, our investigation is the first to propose the efficacy of an internal securement technique in the head and neck region.

Pharyngocutaneous fistula is a major complication of total laryngectomy with catastrophic potential and significant impact on patients' morbidity, length of stay, and healthcare costs.(7) Prior radiation therapy, hypothyroidism, and poor nutritional status have been proposed as risk factors for fistula development.(8),(9),(10),(11) We hypothesized that drain migration from the pharyngeal closure bed would impact PCF formation or detection. Our analysis showed no difference in the incidence of complications between the EO and IE groups. Similarly, there was no difference in the time to detection between the two groups. These trends prompt additional inquiry into the clinical utility of

internal suturing technique, as our smaller sample size prohibits definite conclusions. The rate of PCF development in our cohort was consistent with current ranges of 15-25% for upfront and salvage laryngectomies. Without an established intervention effect size, a high-fidelity sample size estimation could not be calculated. In a post-hoc exercise using a relative effect of 10% risk reduction, power of 80%, and alpha of 0.05, 248 patients would need to be enrolled in each arm of a two-sample study to achieve adequate power.

Pharyngeal closure techniques have been the subject of investigation with conflicting results to date. Avci et al. demonstrated decreased rates of PCF while using a modified continuous Connell suture compared to interrupted submucosal suture for pharyngeal mucosal closure.(12) Deniz et al. concluded that a vertical closure with a Cushing type continuous suture may be more successful than a T shaped closure with interrupted sutures.

(13) Adjunctive interventions including bolstering the suture line with fibrin sealant has been proposed to improve pharyngotomy closure success; however, our own institutional analysis refuted this notion.(14),(15) There are certain limitations to our analysis. The aforementioned sample size was restricted by the retrospective nature of the review. With few occurrences of the secondary outcomes, this data should serve as foundation for larger or multi-institutional studies aimed to investigate relevant clinical implications.

5 | CONCLUSION

This study aimed to determine the efficacy and utility of internally securing surgical drains with suture following a total laryngectomy. The utilization of an internal suture technique to secure surgical drains following total laryngectomy was associated with a decreased rate of drain migration from the pharyngeal closure site. However, there were no differences in the incidence or detection of post-operative complications amongst the EO and IE groups. Studies encompassing larger cohorts are warranted to further investigate the relationship between drain placement and post-operative complications.

REFERENCES

1. Schwartz SR, Yueh B, Maynard C, et al. Predictors of wound complications after laryngectomy: a study of over 2000 patients. *Otolaryngology Head Neck Surg.* 2004; 131:61–68.
2. Samraj K, Gurusamy KS. Wound drains following thyroid surgery. *Cochrane Database Syst Rev.* 2007; Oct 17(4):CD006099.
3. Bastian RW, Park AH. Suction drain management of salivary fistulas. *Laryngoscope.* 1995; 105(12 Pt 1):1337-1341.
4. Heskin L, Cahill V, Filobos G, Regan P, O'Sullivan ST, Bryan K. A new adaptation for a secure surgical drain placement and a comparison with four common drain fixation methods. *Ann R Coll Surg Engl.* 2019;101(1):60-68.
5. Anehosur V, Ghosh R, Joshi A, Jayade B, Kumar N. Drain Tags: A Reliable Method of Securing Drains in the Neck. *Indian J Surg.* 2018;80(1):100-102.
6. Jayaraj SM, Ghufloor K, Patel KS. Surgical technique. Securing of surgical drains in the neck. *Ann R Coll Surg Engl.* 1998; 80(6):438.
7. Kwon D, Genden EM, de Bree R, et al. Overcoming wound complications in head and neck salvage surgery. *Auris Nasus Larynx.* 2018; 45(6):1135-1142.
8. Dedivitis RA, Aires FT, Cernea CR, Brandão LG. Pharyngocutaneous fistula after total laryngectomy: systematic review of risk factors. *Head Neck.* 2015;37(11):1691-1697.
9. Galli J, De Corso E, Volante M, et al. Post laryngectomy pharyngocutaneous fistula: incidence, predisposing factors, and therapy. *Otolaryngology Head Neck Surg.* 2005; 133(5):689–694.
10. White HN, Golden B, Sweeny L, Carroll WR, Magnuson JS, Rosenthal EL. Assessment and incidence of salivary leak following laryngectomy. *Laryngoscope.* 2012; 122(8):1796-1799.

SURGICAL DRAIN PLACEMENT TECHNIQUE AND ITS EFFECTS FOLLOWING TOTAL LARYNGECTOMY

11. Timmermans AJ, Lansaat L, Theunissen EA, et al. Predictive factors for pharyngocutaneous fistulization after total laryngectomy. *Ann Otol Rhinol Laryngol.* 2014; 123:153–161.
12. Avci H, Karabulut B. Is It Important Which Suturing Technique Used for Pharyngeal Mucosal Closure in Total Laryngectomy? Modified Continuous Connell Suture May Decrease Pharyngocutaneous Fistula. *Ear Nose Throat J.* 2020;99(10):664-670.
13. Deniz M, Ciftci Z, Gultekin E. Pharyngoesophageal Suturing Technique May Decrease the Incidence of Pharyngocutaneous Fistula following Total Laryngectomy. *Surg Res Pract.* 2015; 2015:363640.
14. Park J, Chang C, Kwon D. Use of fibrin adhesive for preventing pharyngocutaneous fistula in total laryngectomy. *Am J Otolaryngol.* 2020;41(6):1026-74.
15. Stanisce L, Lai M, Ahmad N, et al. Outcomes Associated with Fibrin Sealant Use in Lateral Neck Dissections. *OTO Open.* 2020;4(4):24739-74X20981021.

How to cite this article: Yekaterina Koshkareva et al. Surgical Drain Placement Technique and Its Effects Following Total Laryngectomy. *Journal of Otolaryngology and Rhinology Research.* 2023;135–140. <https://doi.org/10.52845/JORR/2023/4.3.1>
